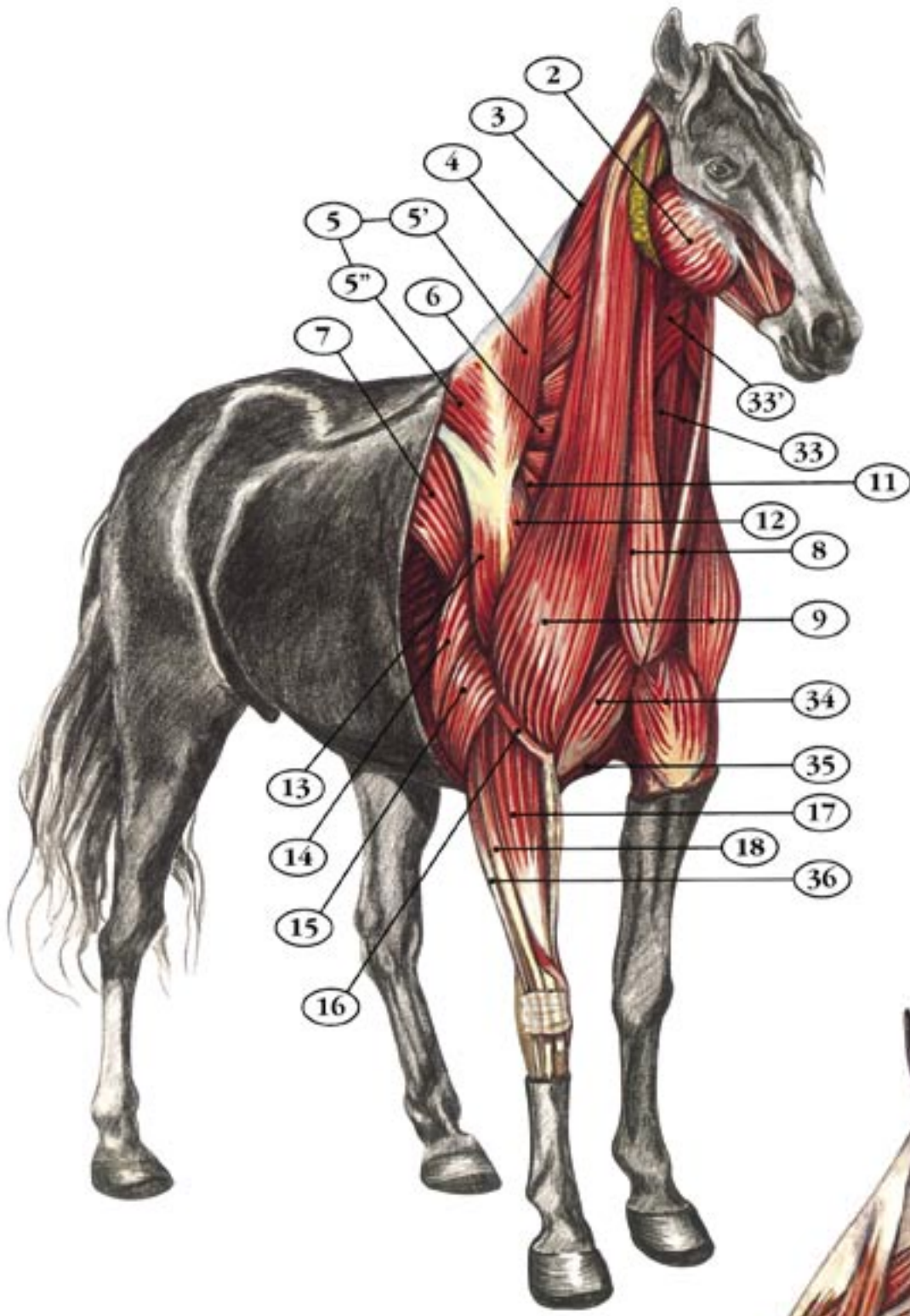
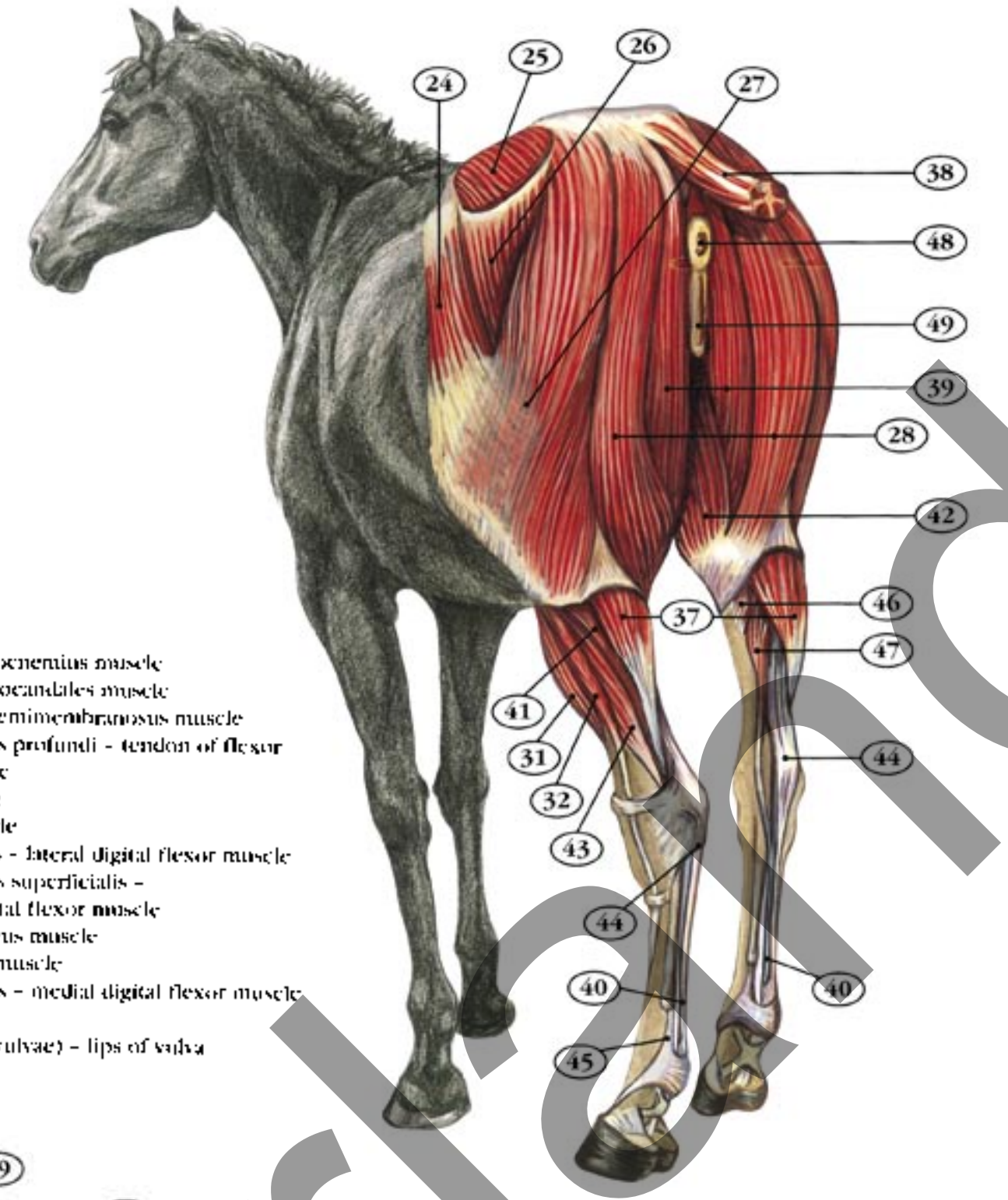


MUSCULATURE OF THE HORSE



OBLIQUE VIEW

- 33 m. sternohyoideus et m. sternothyroideus - sternohyoid muscle and sternothyroid muscle
- 33' m. omohyoideus - omohyoid muscle
- 34 m. pectoralis descendens - descending pectoral muscle
- 35 m. pectoralis transversus - transverse pectoral muscle
- 36 m. extensor digitalis lateralis - lateral digital extensor muscle

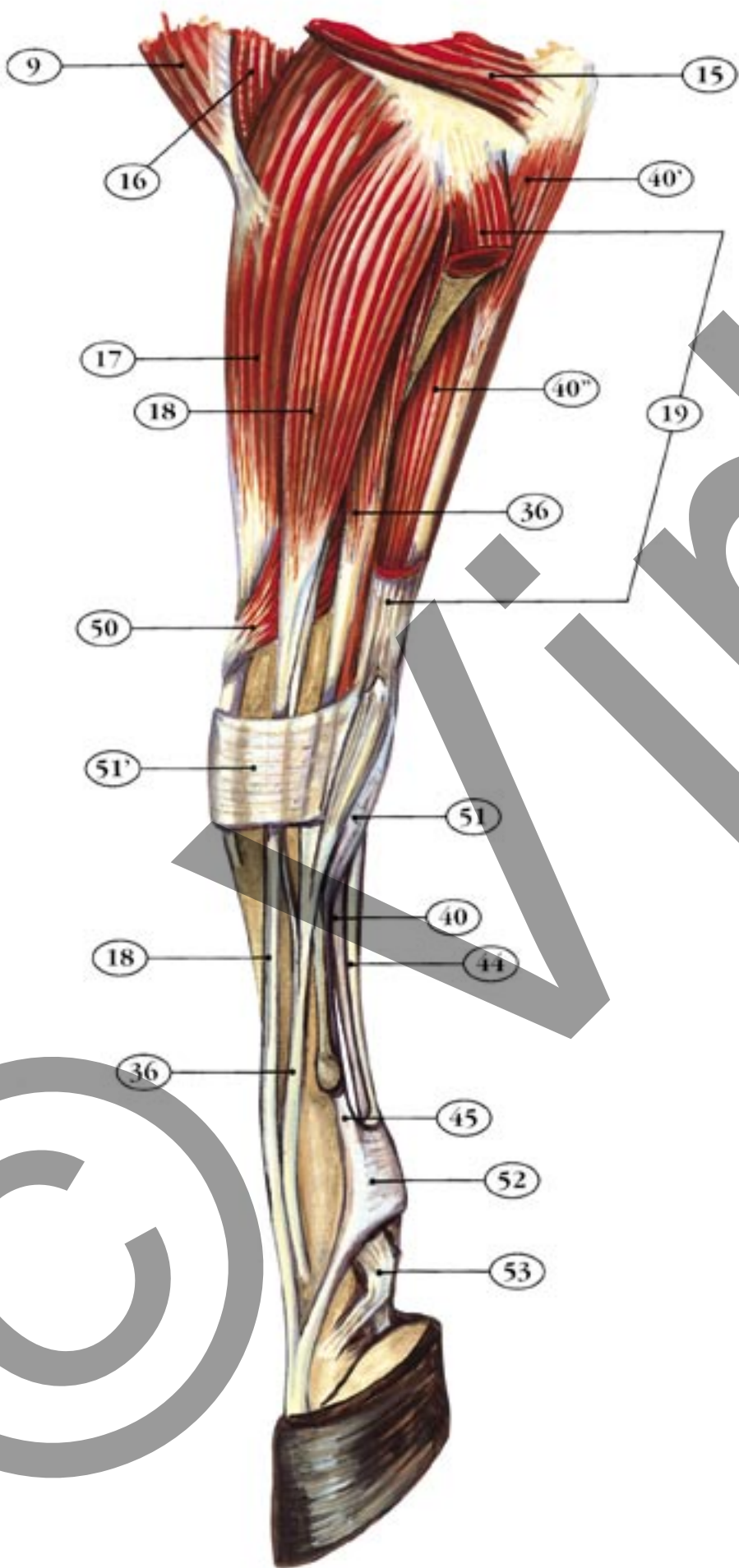
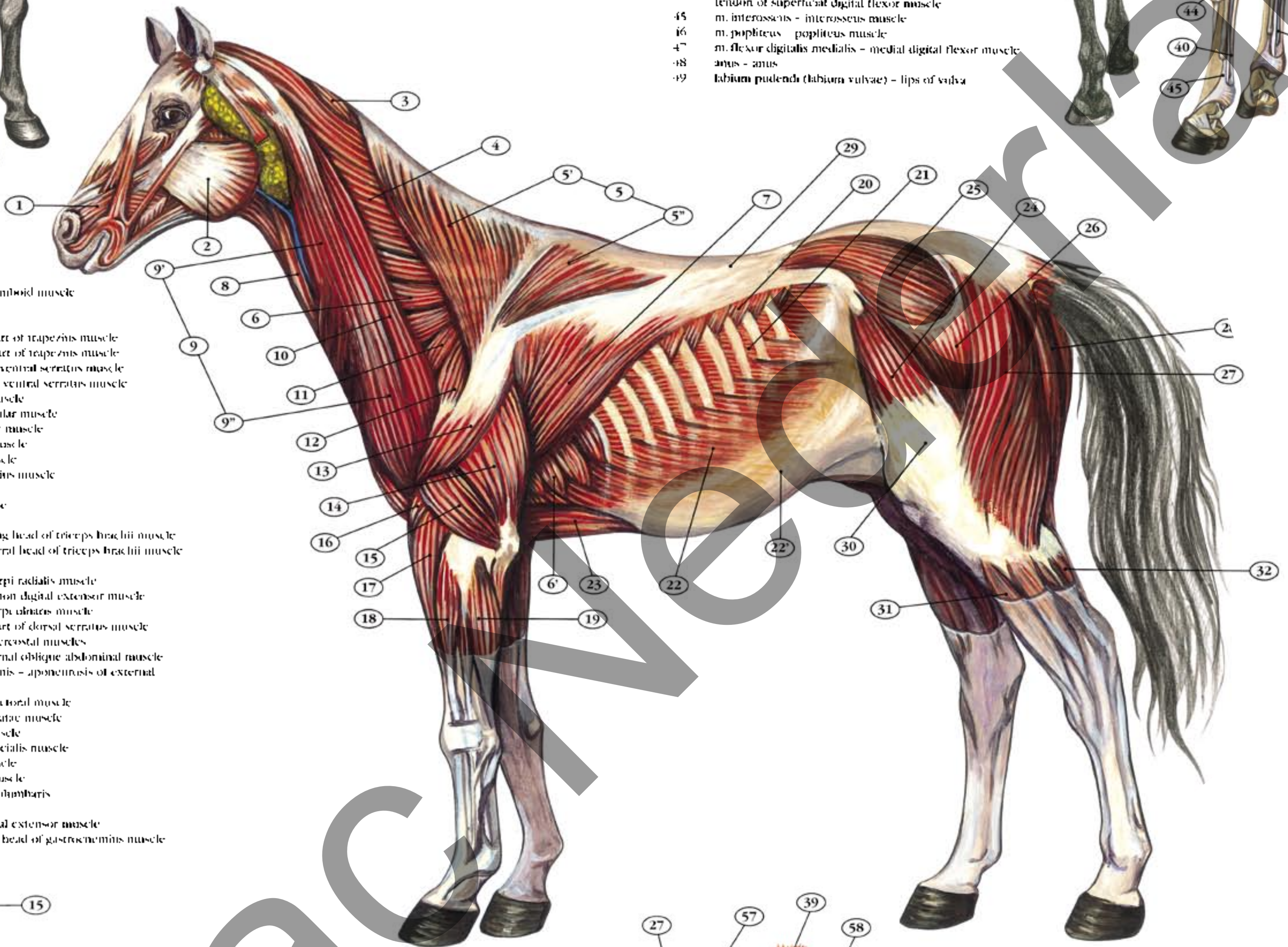


CAUDOLATERAL VIEW

- 37 m. gastrocnemius - gastrocnemius muscle
- 38 mm. sacrocaudales - sacrocaudales muscle
- 39 m. semitendinosus - semitendinosus muscle
- 40 tendo m. flexoris digitalis profundus - tendon of flexor digitalis profundus muscle
- 41 m. soleus - soleus muscle
- 42 m. gracilis - gracilis muscle
- 43 m. flexor digitalis lateralis - lateral digital flexor muscle
- 44 tendo m. flexoris digitalis superficialis - tendon of superficial digital flexor muscle
- 45 m. interosseus - interosseus muscle
- 46 m. popliteus - popliteus muscle
- 47 m. flexor digitalis medialis - medial digital flexor muscle
- 48 anus - anus
- 49 labium pendens (labium vulvae) - lips of vulva

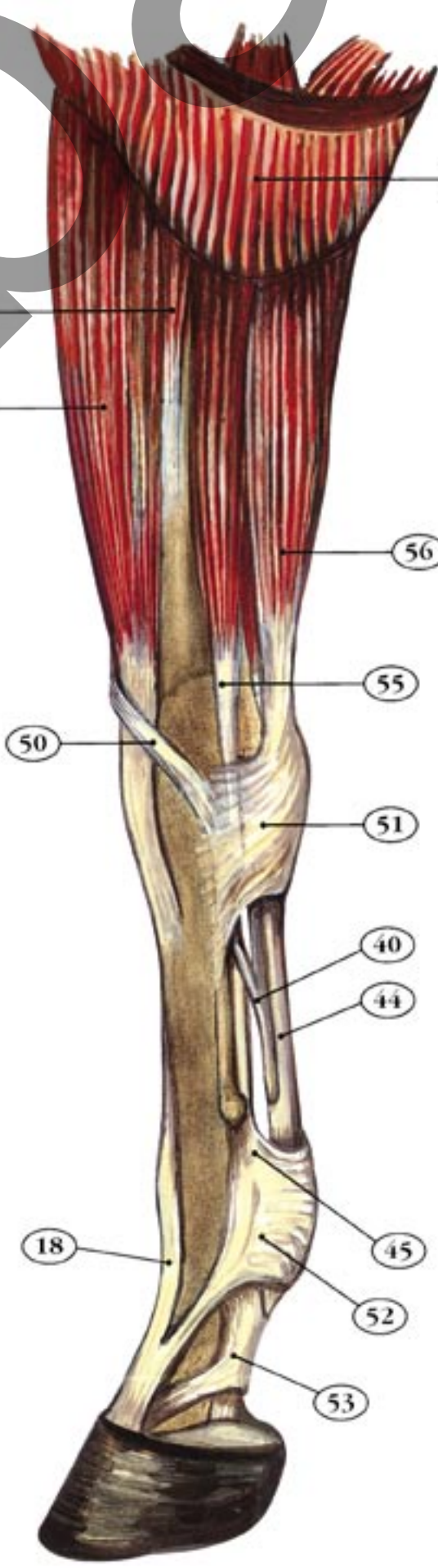SUPERFICIAL VIEW

- 1 m. caninus - caninus muscle
- 2 m. masseter - masseter muscle
- 3 m. rhomboideus cervicalis - cervical rhomboid muscle
- 4 m. splenius - splenius muscle
- 5 m. trapezius - trapezius muscle
- 5' pars cervicalis m. trapezi - cervical part of trapezius muscle
- 5'' pars thoracica m. trapezi - thoracic part of trapezius muscle
- 6 m. serratus ventralis cervicalis - cervical ventral serratus muscle
- 6' m. serratus ventralis thoracicus - thoracic ventral serratus muscle
- 7 m. latissimus dorsi - latissimus dorsi muscle
- 8 m. sternomandibularis - sternomandibular muscle
- 9 m. brachiocephalicus - brachiocephalic muscle
- 9' m. cleidomastoidaeus - cleidomastoid muscle
- 9'' m. cleidobrachialis - cleidobrachial muscle
- 10 m. omotraversarius - omotraversarius muscle
- 11 m. subclavius - subclavius muscle
- 12 m. supraspinatus - supraspinatus muscle
- 13 m. deltoideus - deltoid muscle
- 14 caput longum m. tricipitis brachii - long head of triceps brachii muscle
- 15 caput laterale m. tricipitis brachii - lateral head of triceps brachii muscle
- 16 m. brachialis - brachialis muscle
- 17 m. extensor carpi radialis - extensor carpi radialis muscle
- 18 m. extensor digitorum communis - common digital extensor muscle
- 19 m. extensor carpi ulnaris - extensor carpi ulnaris muscle
- 20 m. serratus dorsalis caudalis - caudal part of dorsal serratus muscle
- 21 mm. intercostales externi - external intercostal muscles
- 22 m. obliquus externus abdominalis - external oblique abdominal muscle
- 22' aponeurosis m. obliqui externi abdominalis - aponeurosis of external abdominal oblique muscle
- 25 m. pectoralis ascendens - ascending pectoral muscle
- 21' m. tensor fasciae latae - tensor fasciae latae muscle
- 25' m. gluteus medius - gluteus medius muscle
- 26 m. gluteus superficialis - gluteal superficialis muscle
- 27 m. biceps femoris - biceps femoris muscle
- 28 m. semitendinosus - semitendinosus muscle
- 29 fascia thoracolumbaris - fascia thoracolumbaris
- 30 fascia lata - fascia lata
- 31 m. extensor digitalis longus - long digital extensor muscle
- 32 caput laterale m. gastrocnemii - lateral head of gastrocnemius muscle



MUSCLES OF THE THORACIC LIMB LATERAL VIEW

- 40 tendo m. flexoris digitalis profundus - tendon of flexor digitalis profundus muscle
- 40' caput ulnare m. flexoris digitalis profundus - ulnar head of deep digital flexor muscle
- 40'' caput humerale m. flexoris digitalis profundus - humeral head of deep digital flexor muscle
- 50 m. abductor digiti primii longus - abductor digiti I longus muscle
- 51 retinaculum flexorium - transverse ligament of the carpus
- 51' retinaculum extensorium - dorsal annular ligament of the carpus
- 52 lig. metacarpum transversum superiorem - annular ligament of fetlock
- 54 lig. annulare digiti - digital annular ligament

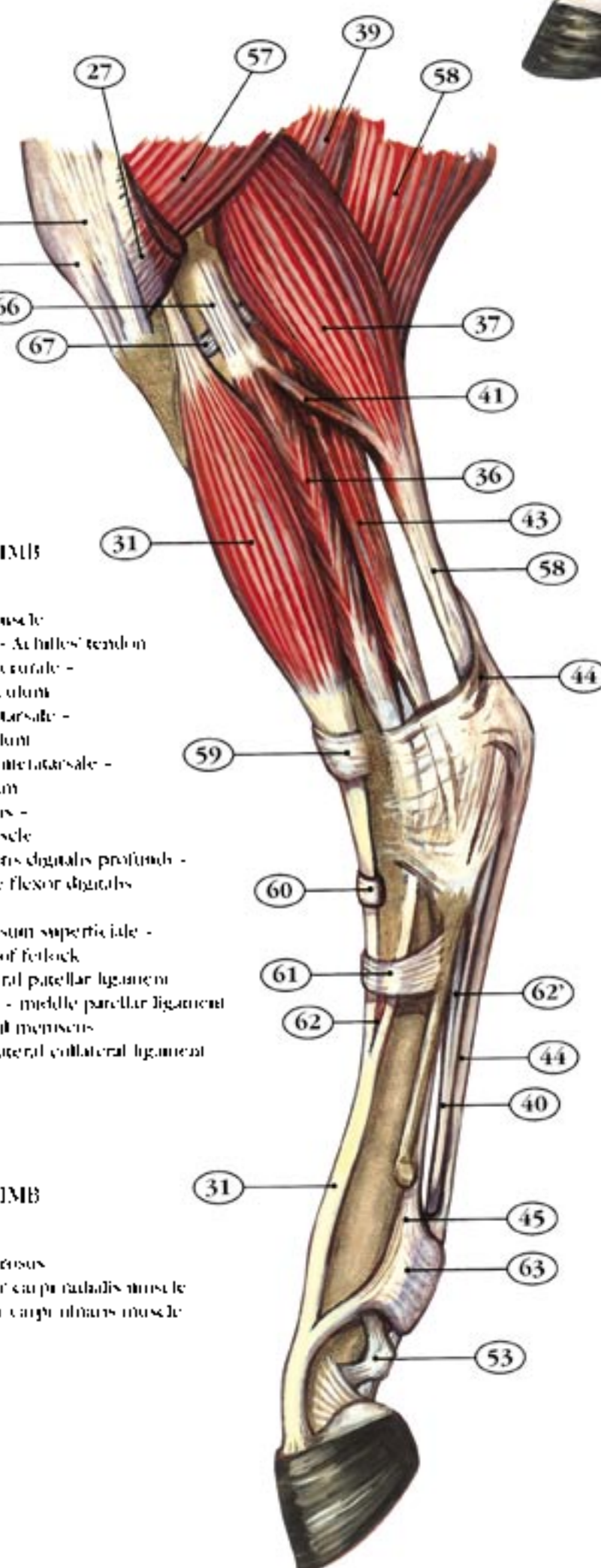


MUSCLES OF THE PELVIC LIMB LATERAL VIEW

- 57 m. adductor - adductor muscle
- 58 tendo m. tricipitis surae - Achilles' tendon
- 59 retinaculum extensorium crurale - proximal extensor retinaculum
- 60 retinaculum extensorium tarsale - middle extensor retinaculum
- 61 retinaculum extensorium distalare - distal extensor retinaculum
- 62 m. extensor digitorum brevis - short digital extensor muscle
- 62' fig. accessorium m. flexoris digitalis profundus - accessory ligament of the flexor digitalis profundus muscle
- 64 fig. metatarsum transversum superiorem - palmar annular ligament of fetlock
- 64' lig. patellae laterale - lateral patellar ligament
- 65 lig. patellae intermedium - middle patellar ligament
- 66 m. extensor lateralis - lateral meniscus
- 67 lig. collaterale laterale - lateral collateral ligament

MUSCLES OF THE THORACIC LIMB MEDIAL VIEW

- 51' lacertus fibrosus - lacertus fibrosus
- 55 m. flexor carpi radialis - flexor carpi radialis muscle
- 56 m. flexor carpi ulnaris - flexor carpi ulnaris muscle



MUSCLES OF THE PELVIC LIMB MEDIAL VIEW

- 68 m. peroneus tertius - peroneus tertius muscle
- 69 m. tibialis cranialis - cranial tibial muscle
- 70 m. quadriceps (vastus medialis) - quadriceps (medial part) muscle
- 71 m. peroneus - peroneus muscle
- 72 m. sartorius - sartorius muscle
- 73 m. tibialis caudalis - caudal tibial muscle

