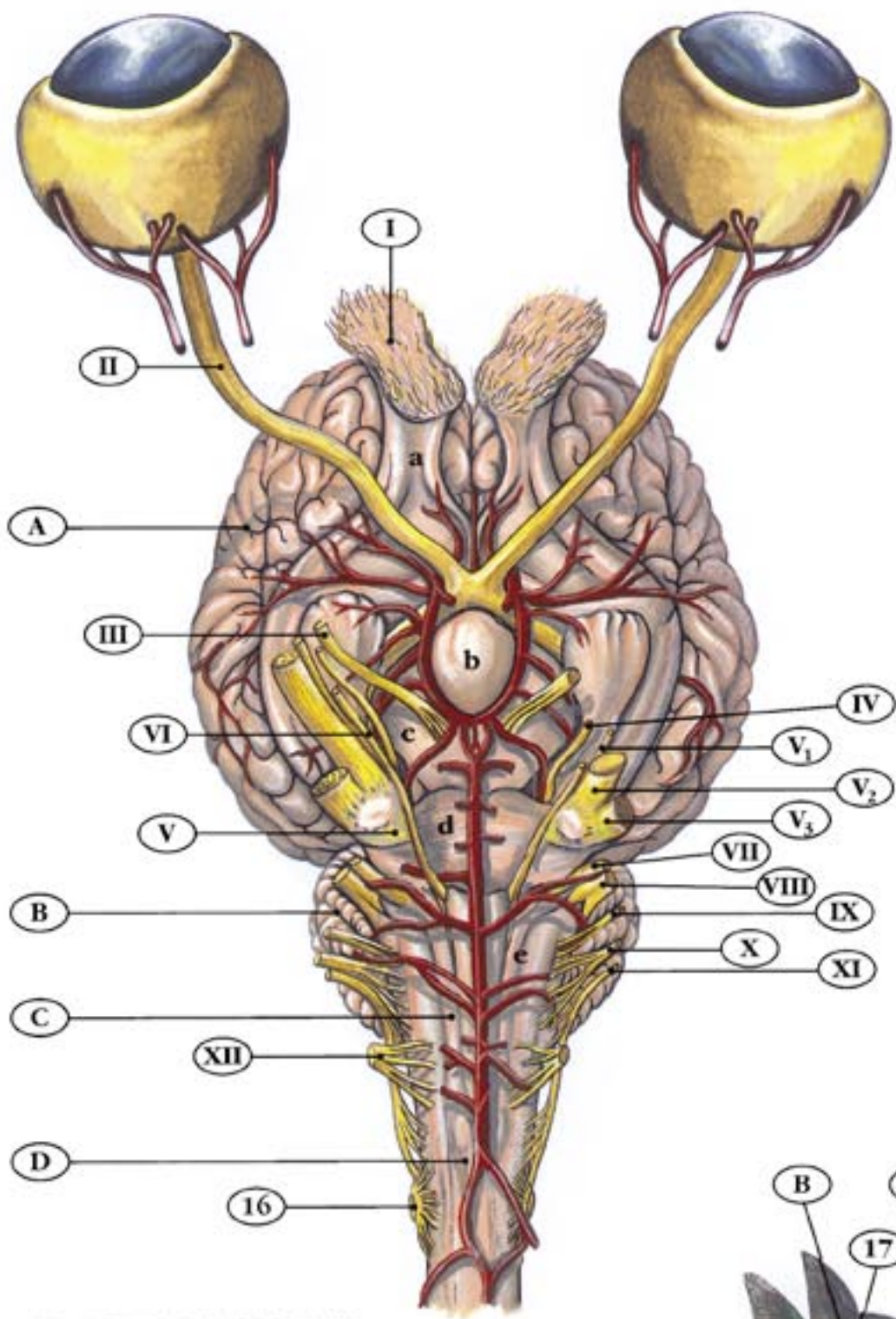
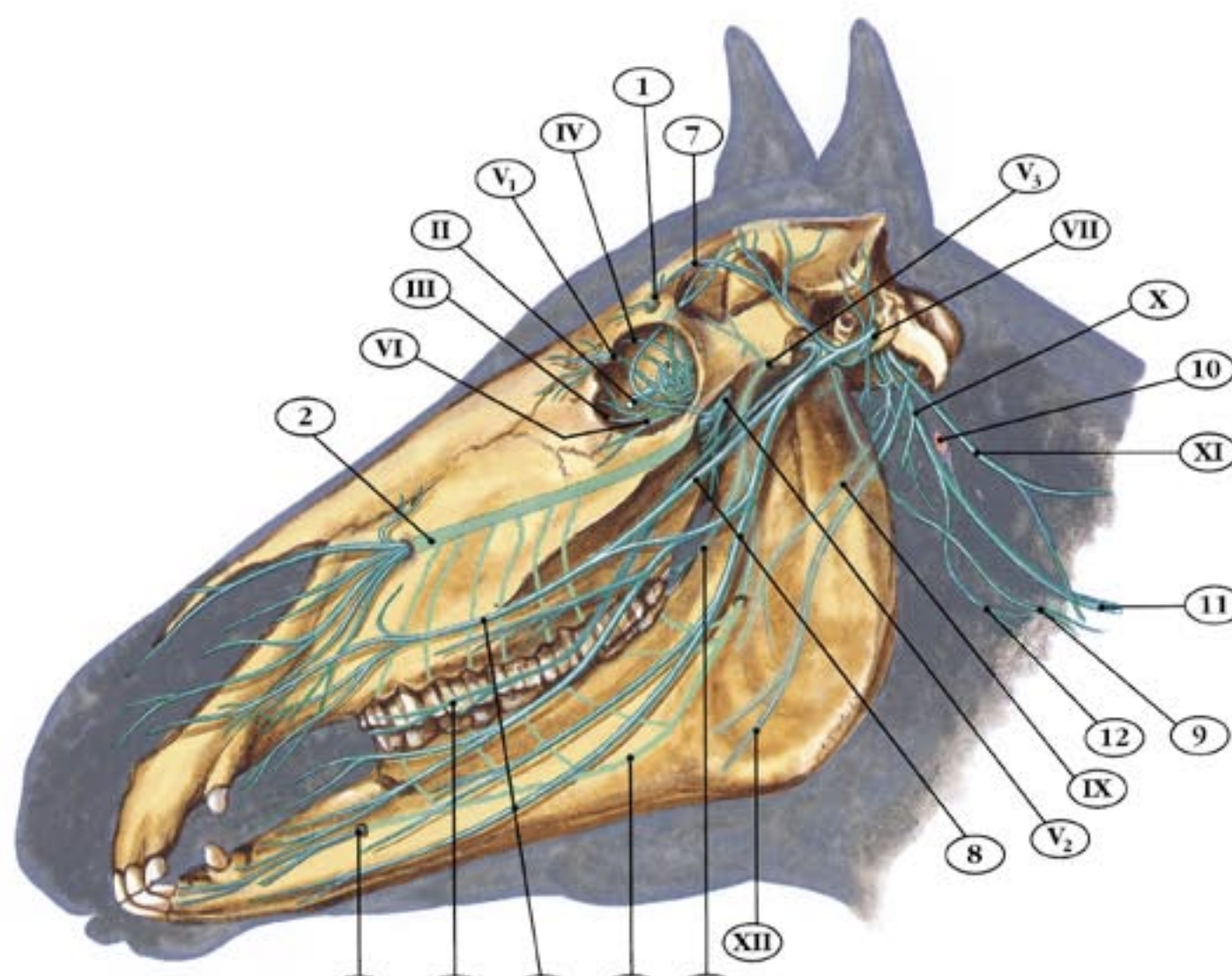


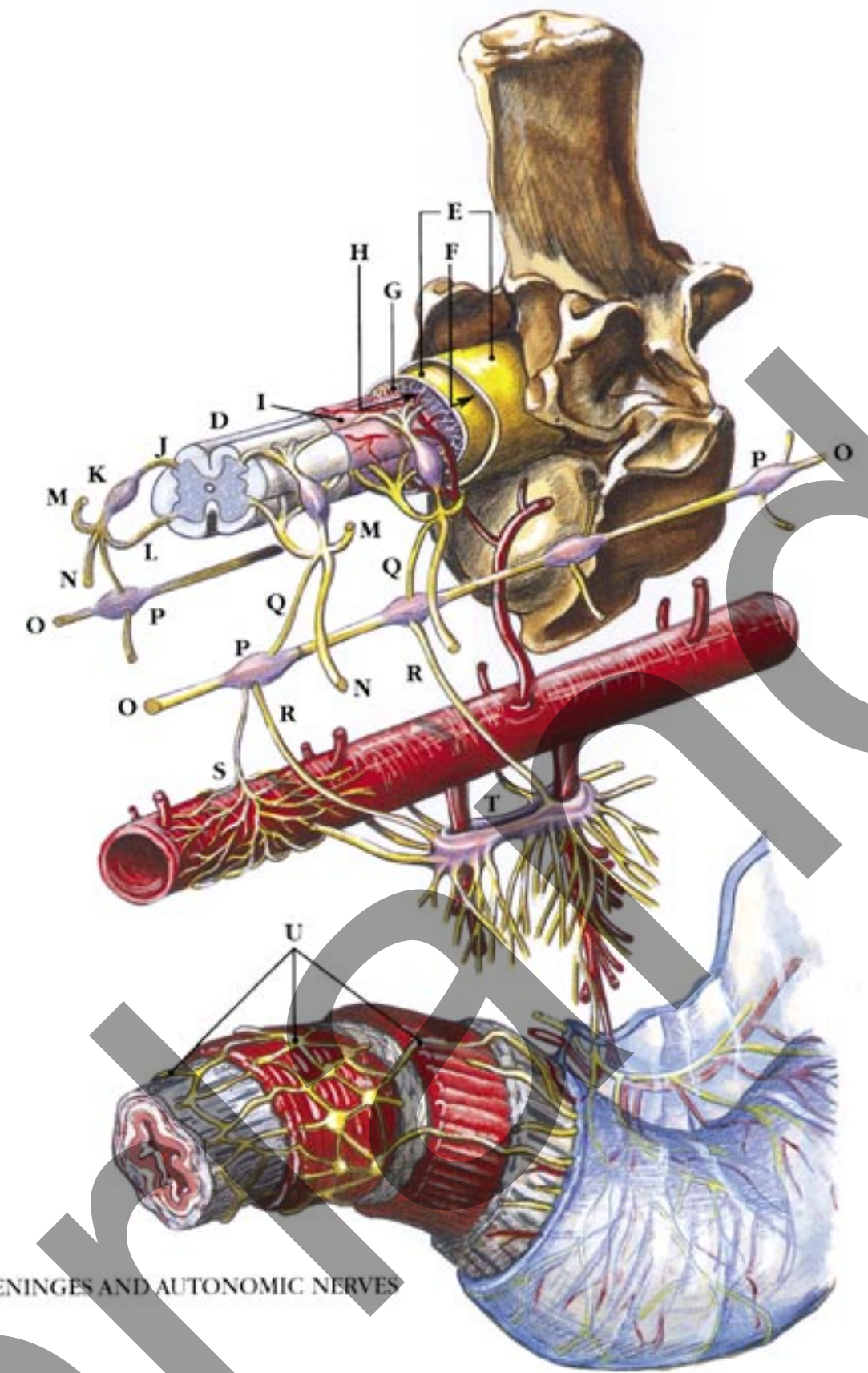
NERVOUS SYSTEM OF THE HORSE



VENTRAL VIEW OF THE BRAIN



CRANIAL NERVES LEFT LATERAL VIEW

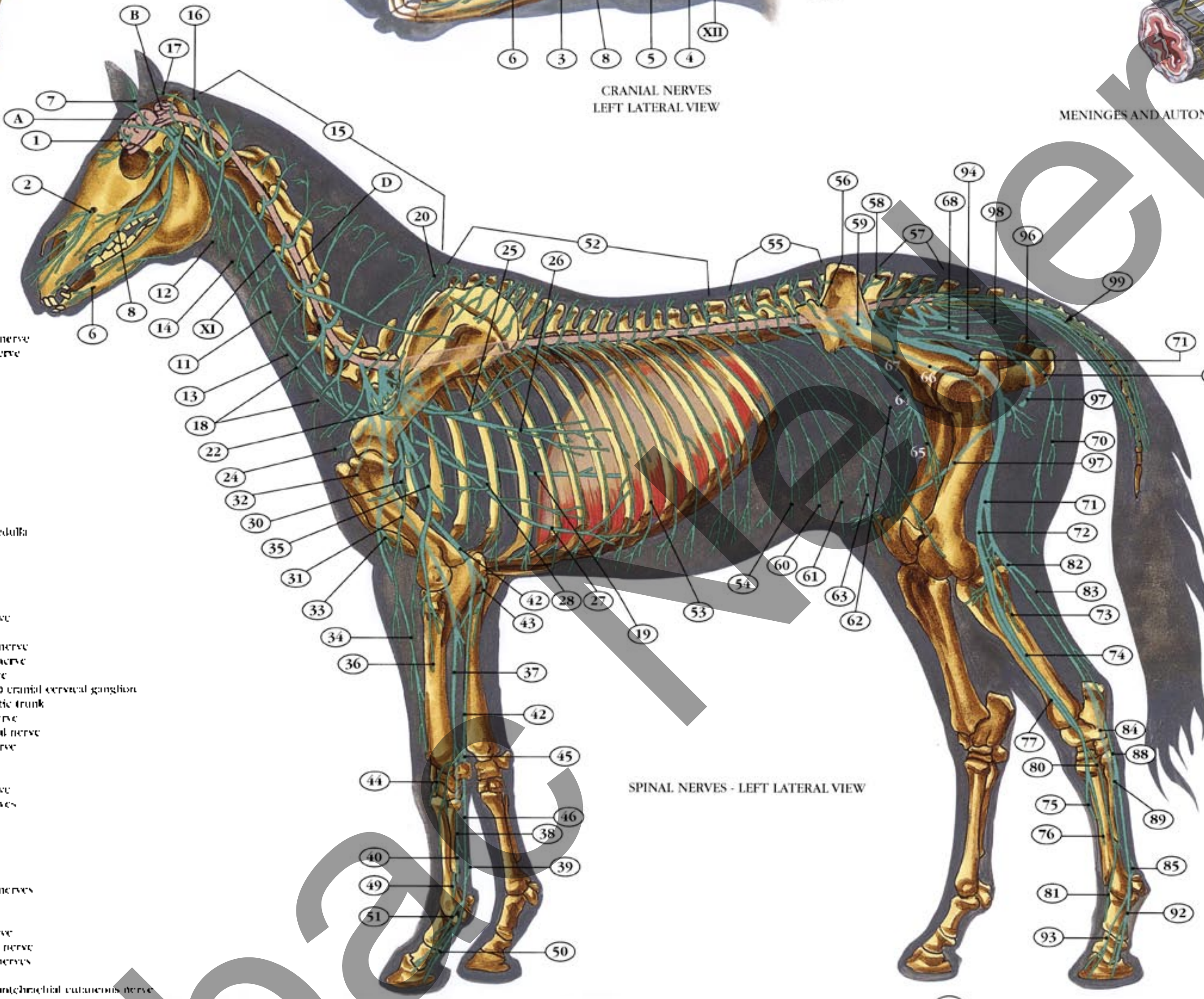


MENINGES AND AUTONOMIC NERVES

- I n. olfactorius - olfactory nerves
- II n. opticus - optic nerve
- III n. oculomotorius - oculomotor nerve
- IV n. trochlearis - trochlear nerve
- V n. trigeminus - trigeminal nerve
- V₁ n. ophthalmicus - ophthalmic nerve
- V₂ n. maxillaris - maxillary nerve
- V₃ n. mandibularis - mandibular nerve
- VI n. abducens - abducens nerve
- VII n. facialis - facial nerve
- VIII n. vestibulocochlearis - vestibulocochlear nerve
- IX n. glossopharyngeus - glossopharyngeal nerve
- X n. vagus - vagus nerve
- XI n. accessorius - accessory nerve
- XII n. hypoglossus - hypoglossal nerve

- A cerebrum - cerebrum
- B cerebellum - cerebellum
- C truncus encephali - brainstem
- a rhinencephalon - rhinencephalon
- b hypophysis - hypophysis (pituitary gland)
- c mesencephalon - mesencephalon
- d metencephalon (pons) - metencephalon
- e myelencephalon (medulla oblongata) - medulla

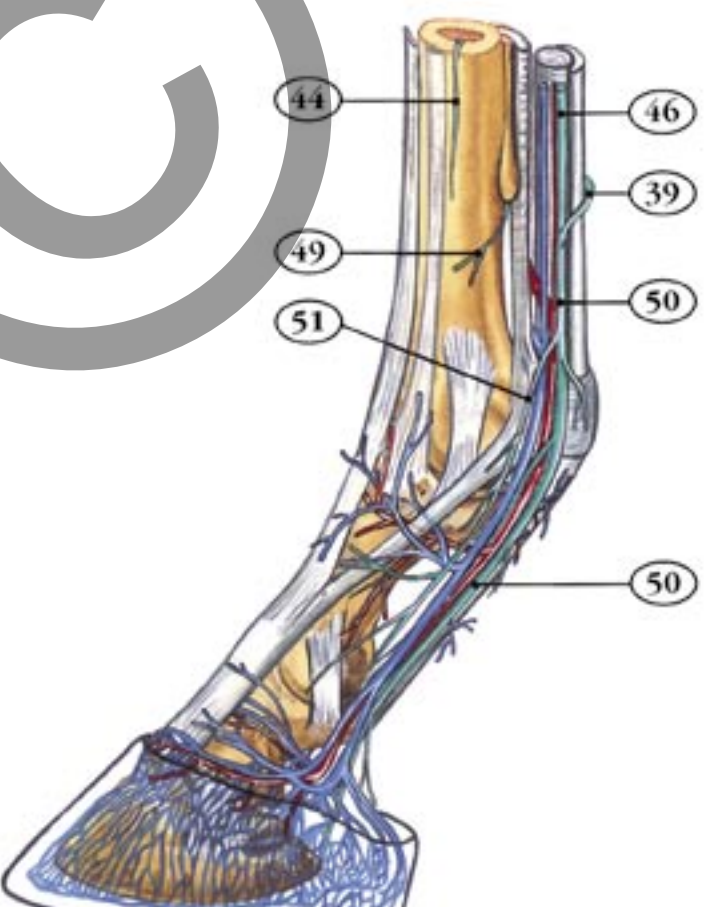
- 1 n. supraorbitalis - supraorbital nerve
- 2 n. infraorbitalis - infraorbital nerve
- 3 n. buccalis - buccal nerve
- 4 n. lingualis - lingual nerve
- 5 n. alveolaris inferior - inferior alveolar nerve
- 6 n. mentalis - mental nerve
- 7 n. auriculopalpebralis - auriculopalpebral nerve
- 8 rami buccales - buccal branches of facial nerve
- 9 ramus colli - cervical branch of facial nerve
- 10 ganglion cervicale craniale - (sympathetic) cranial cervical ganglion
- 11 truncus vagosympathicus - vagosympathetic trunk
- 12 n. laryngeus cranialis - cranial laryngeal nerve
- 13 n. laryngeus recurrens - recurrent laryngeal nerve
- 14 n. laryngeus caudalis - caudal laryngeal nerve
- 15 nn. cervicales - cervical nerves
- 16 n. cervicalis I - first cervical nerve
- 17 n. auricularis magnus - great auricular nerve
- 18 nn. supraclaviculares - supraclavicular nerves
- 19 n. phrenicus - phrenic nerve
- 20 n. cervicalis VIII - eighth cervical nerve
- 21 plexus brachialis - brachial plexus
- 22 n. suprascapularis - suprascapular nerve
- 23 nn. subscapulares - subscapular nerves
- 24 nn. pectorales craniales - cranial pectoral nerves
- 25 n. thoracodorsalis - thoracodorsal nerve
- 26 n. thoracicus longus - long thoracic nerve
- 27 n. thoracicus lateralis - lateral thoracic nerve
- 28 n. intercostobrachialis - intercostobrachial nerve
- 29 nn. pectorales caudales - caudal pectoral nerves
- 30 n. axillaris - axillary nerve
- 31 n. cutaneus antebrachii cranialis - cranial antebrachial cutaneous nerve
- 32 ramus muscularis proximalis nervi musculocutanei - proximal muscular branch of musculocutaneous nerve
- 33 ramus muscularis distalis nervi musculocutanei - distal muscular branch of musculocutaneous nerve
- 34 n. cutaneus antebrachii medialis - medial antebrachial cutaneous nerve
- 35 n. radialis - radial nerve
- 36 n. cutaneus antebrachii lateralis - lateral antebrachial cutaneous nerve
- 37 n. medianus - median nerve
- 38 n. palmaris medialis - medial palmar nerve
- 39 ramus communicans - communicating branch (between # 38 and # 40)
- 40 n. digitalis palmaris medialis - medial (palmar) digital nerve
- 41 ramus dorsalis - dorsal branch (of # 40)
- 42 n. ulnaris - ulnar nerve
- 43 n. cutaneus antebrachii caudalis - caudal antebrachial cutaneous nerve
- 44 ramus dorsalis - dorsal branch of ulnar nerve
- 45 ramus palmaris - palmar branch of ulnar nerve
- 46 n. palmaris lateralis - lateral palmar nerve
- 47 ramus profundus - deep branch (of # 46)
- 48 n. metacarpeus palmaris II - medial palmar metacarpal nerve
- 49 n. metacarpeus palmaris III - lateral palmar metacarpal nerve
- 50 n. digitalis palmaris lateralis - lateral (palmar) digital nerve
- 51 ramus dorsalis - dorsal branch (of # 50)



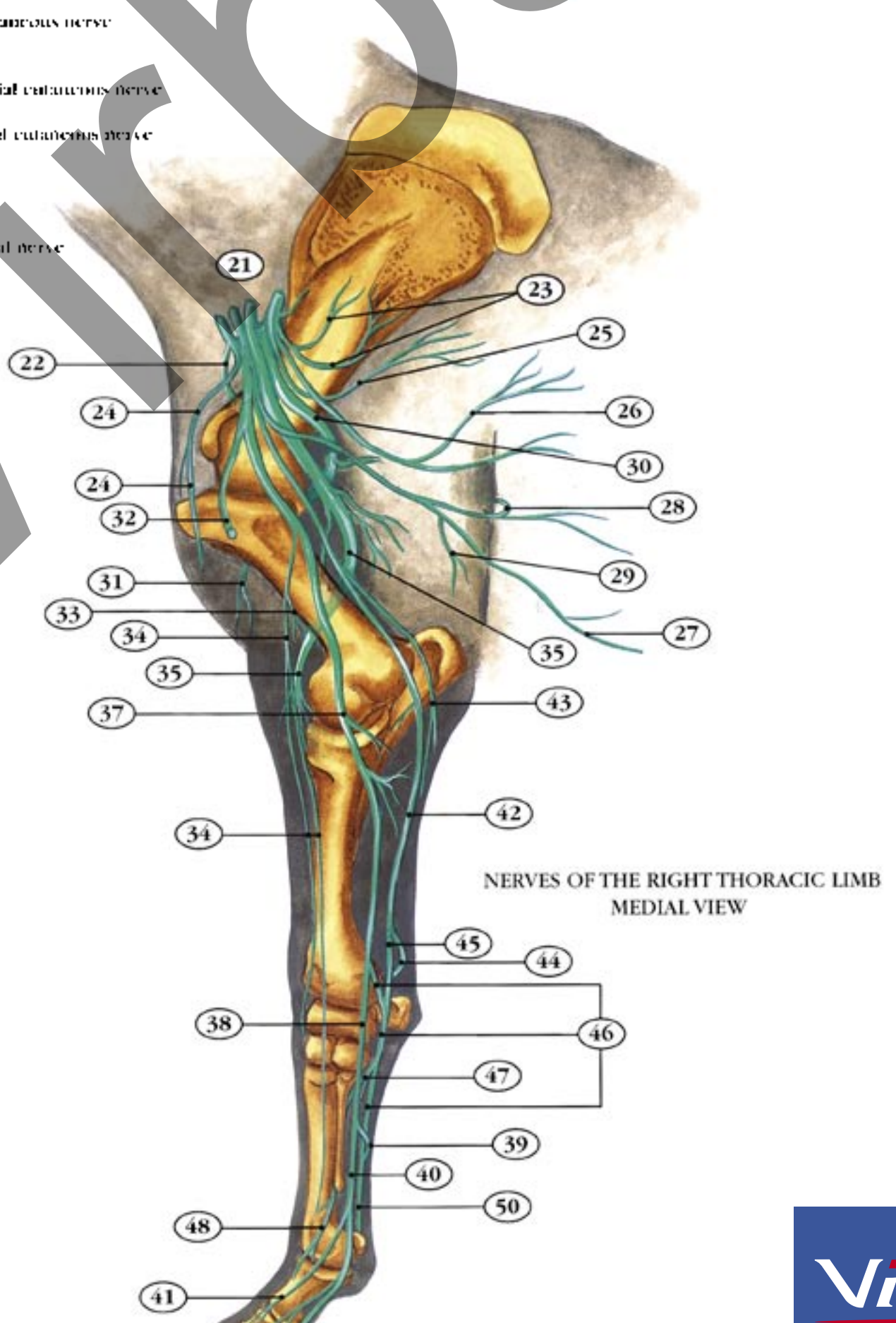
SPINAL NERVES - LEFT LATERAL VIEW

- D medulla spinalis - spinal cord
- E dura mater spinalis - spinal dura mater
- F cavum epineurale - epineurial cavity
- G arachnoidea spinalis - spinal arachnoid
- H cavum subarachnoideale - subarachnoid cavity
- I pia mater spinalis - spinal pia mater
- J radix dorsalis - dorsal root of spinal nerve
- K ganglion spinale - spinal ganglion
- L radix ventralis - ventral root of spinal nerve
- M ramus dorsalis - dorsal branch of spinal nerve
- N ramus ventralis - ventral branch of spinal nerve
- O truncus sympathicus - sympathetic trunk
- P ganglion trunci sympathici - thoracic (paravertebral) sympathetic ganglion
- Q ramus communicans - communicating branch
- R rami splanchnici - splanchnic branches
- S n. plexus thoracicus - plexus thoracicus
- T ganglia celiacum et mesentericum caudale - (prevertebral) sympathetic ganglia
- U plexus celiacus - celiac plexus

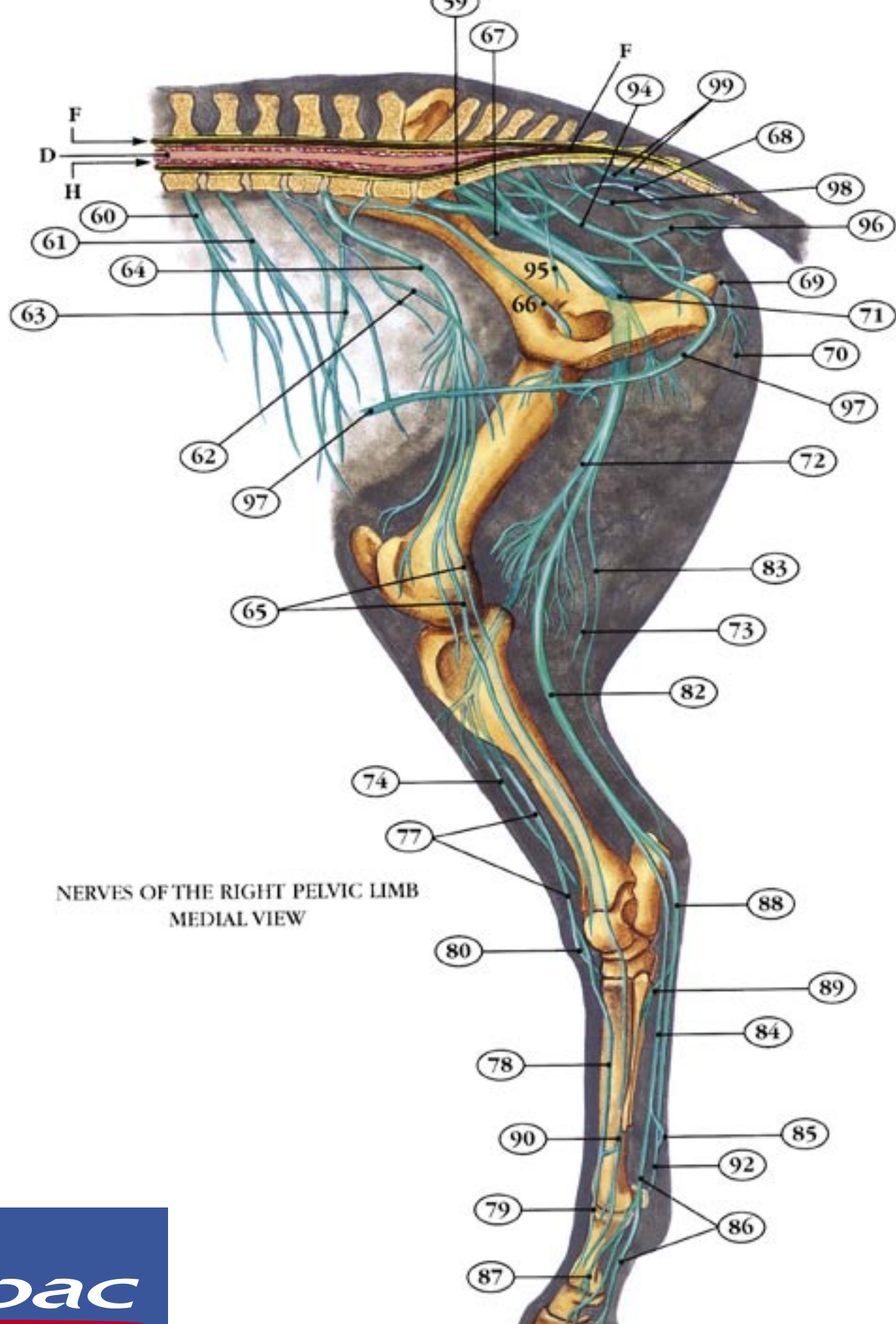
- 52 nn. thoracici - thoracic nerves
- 53 nn. intercostales - intercostal nerves
- 54 n. costobrombitalis - costobrombital nerve
- 55 nn. lumbales - lumbar nerves
- 56 nn. clunium craniales - cranial clunial nerves
- 57 nn. sacrales - sacral nerves
- 58 nn. clunium media - middle clunial nerves
- 59 plexus lumbosacralis - lumbosacral plexus
- 60 n. alioqui positionis - alioqui positionis nerve
- 61 n. ilioinguinalis - ilioinguinal nerve
- 62 n. genitofemoralis - genitofemoral nerve
- 63 n. cutaneus femoris lateralis - lateral femoral cutaneous nerve
- 64 n. femoralis - femoral nerve
- 65 n. saphenus - saphenous nerve
- 66 n. obturatorius - obturator nerve
- 67 n. gluteus cranialis - cranial gluteal nerve
- 68 n. gluteus caudalis - caudal gluteal nerve
- 69 n. cutaneus femoris caudalis - caudal femoral cutaneous nerve
- 70 nn. clunium caudales - caudal clunial nerves
- 71 n. ischiadicus - sciatic nerve (ischial nerve)
- 72 n. peroneus communis - common peroneal (or fibular) nerve
- 73 n. cutaneus surae lateralis - lateral sural cutaneous nerve
- 74 n. peroneus superficialis - superficial peroneal (or fibular) nerve
- 75 ramus dorsalis - dorsal branch (of # 74)
- 76 ramus lateralis - lateral branch (of # 74)
- 77 n. peroneus profundus - deep peroneal (or fibular) nerve
- 78 n. metatarsus dorsalis II - medial dorsal metatarsal nerve
- 79 n. digitalis dorsalis III medialis - medial dorsal digital nerve
- 80 n. metatarsus dorsalis III - lateral dorsal metatarsal nerve
- 81 n. digitalis dorsalis III lateralis - lateral dorsal digital nerve
- 82 n. tibialis - tibial nerve
- 83 n. cutaneus surae caudalis - caudal sural cutaneous nerve
- 84 n. plantaris medialis - medial plantar nerve
- 85 ramus communicans - communicating branch (between # 84 and # 86)
- 86 n. digitalis plantaris medialis - medial (plantar) digital nerve
- 87 ramus dorsalis - dorsal branch (of # 86)
- 88 n. plantaris lateralis - lateral plantar nerve
- 89 n. metatarsus plantaris II - medial plantar metatarsal nerve
- 90 n. metatarsus plantaris III - lateral plantar metatarsal nerve
- 91 n. digitalis plantaris lateralis - lateral (plantar) digital nerve
- 92 ramus dorsalis - dorsal branch (of # 92)
- 93 n. pudendus - pudendal nerve
- 94 nn. pelvini - (parasympathetic) pelvic nerves
- 95 nn. perineales - perineal nerves
- 96 n. dorsalis penis - dorsal nerve of the penis
- 97 nn. rectales caudales - caudal rectal nerves
- 98 nn. caudales - caudal nerves
- 99



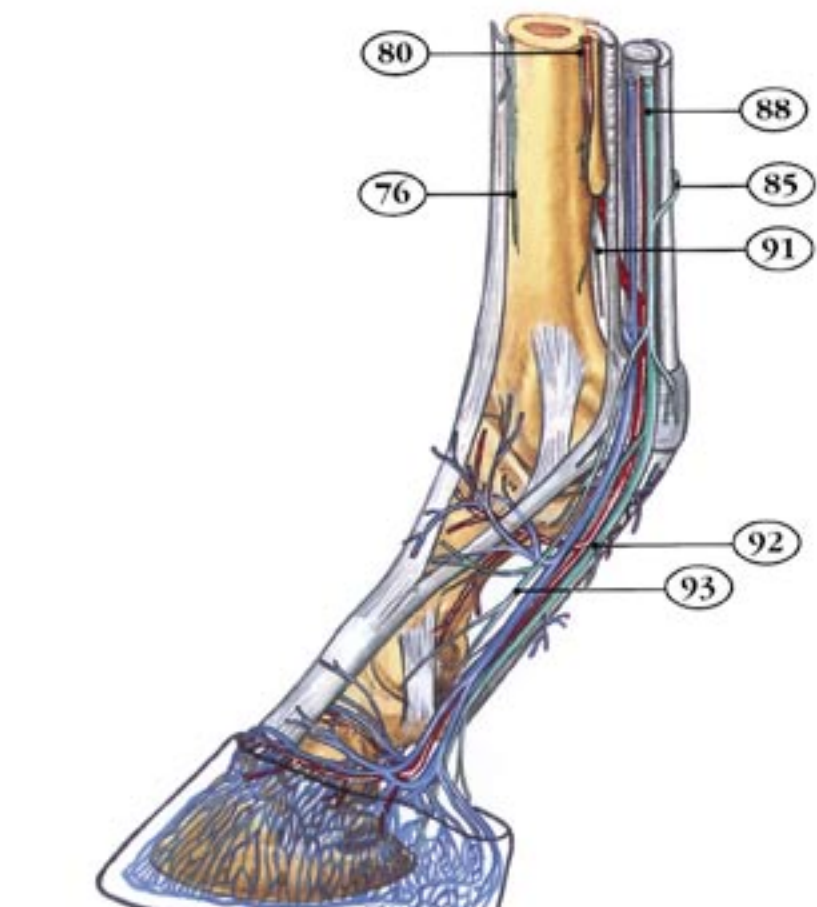
LEFT FOREFOOT - LATERAL VIEW



NERVES OF THE RIGHT THORACIC LIMB MEDIAL VIEW



NERVES OF THE RIGHT PELVIC LIMB MEDIAL VIEW



LEFT HINDFOOT - LATERAL VIEW

