Anatomy of the cat

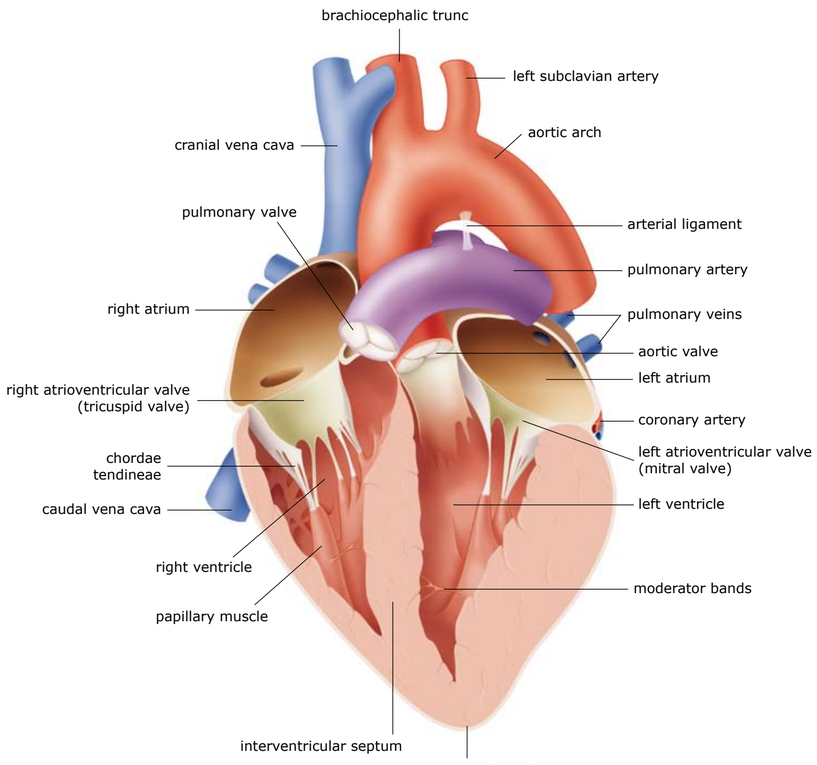

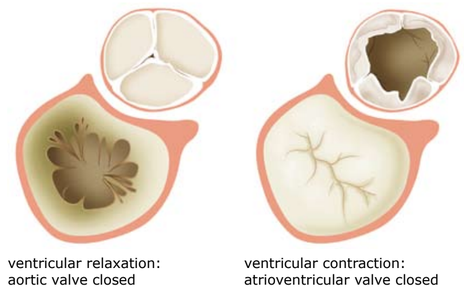

contraction of papillary muscles during ventricular contraction

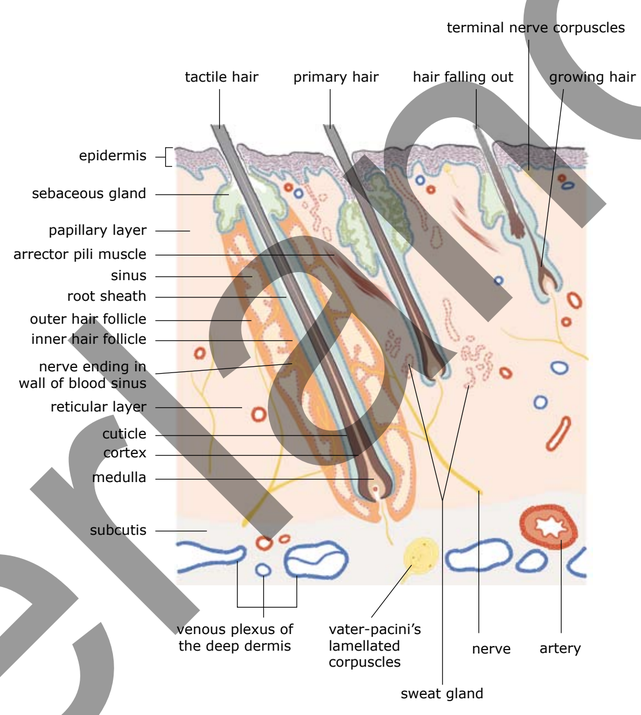

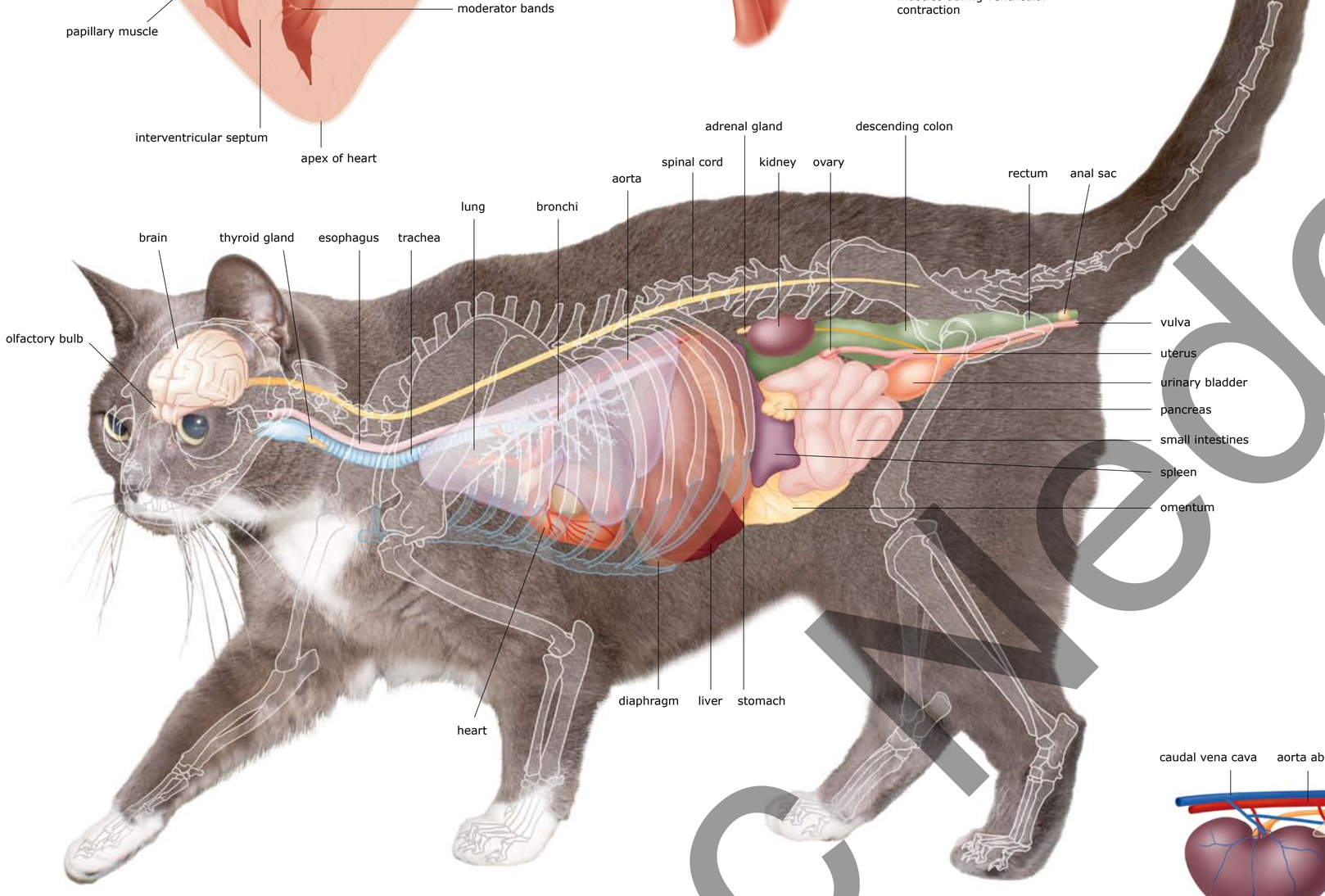

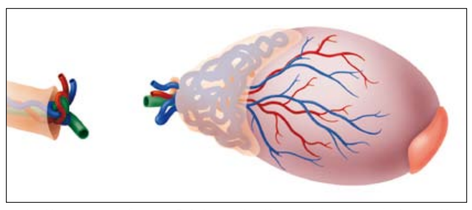

castration; vas deferens & internaltesticular bloodsupply is knotted

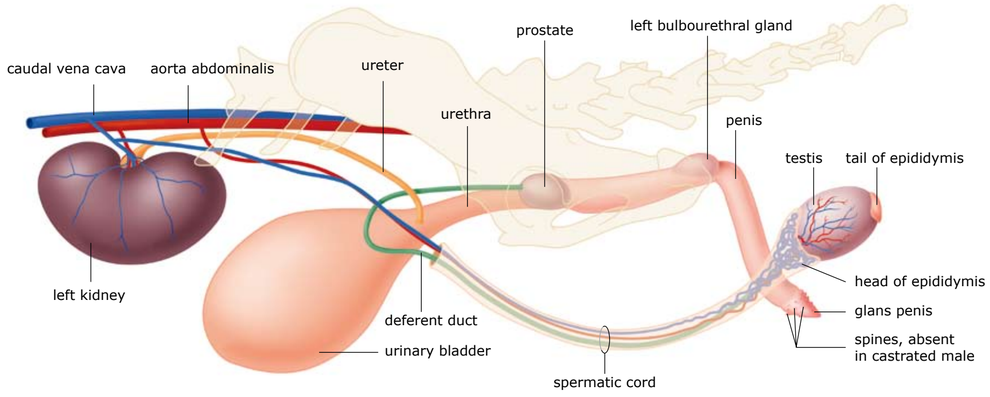

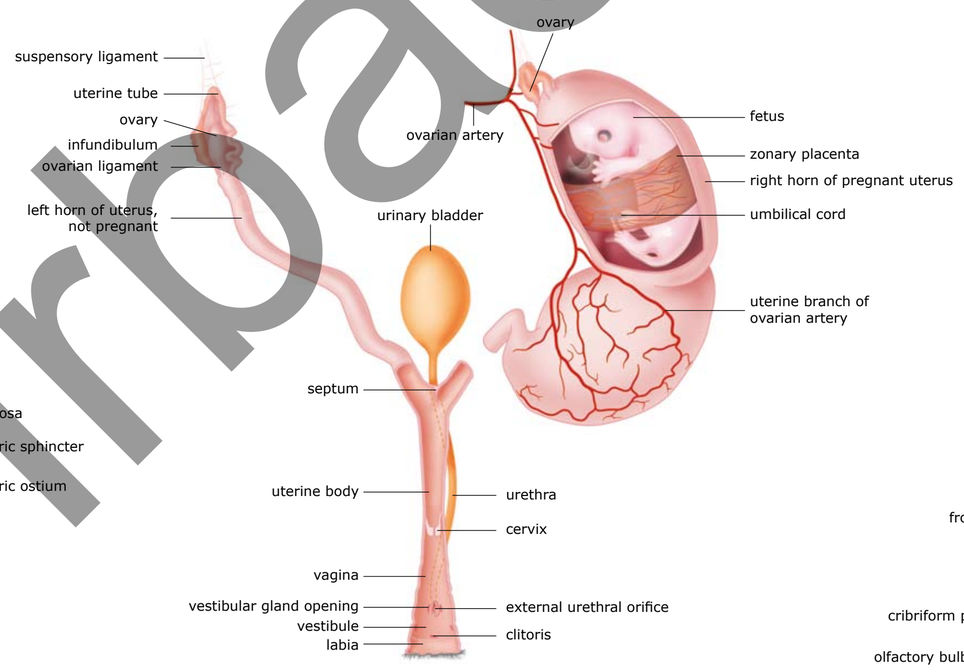

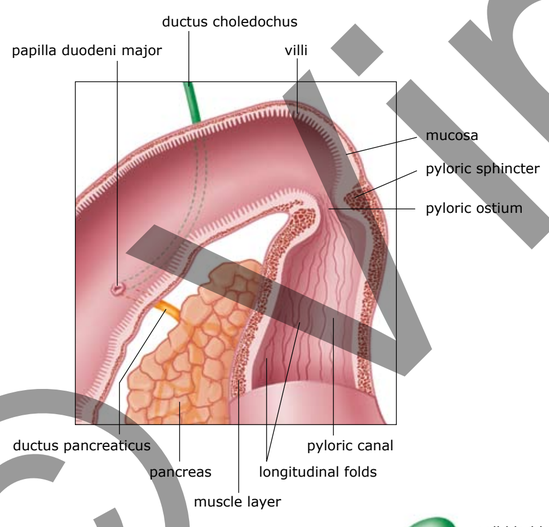

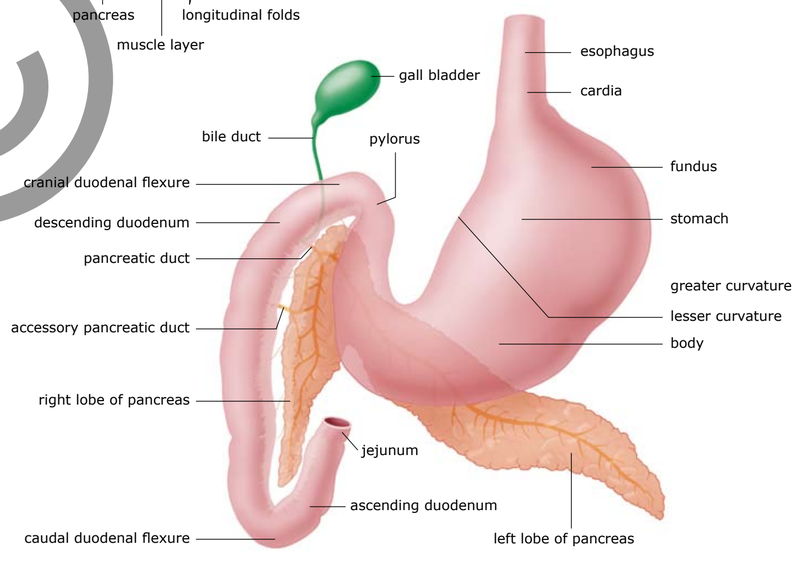

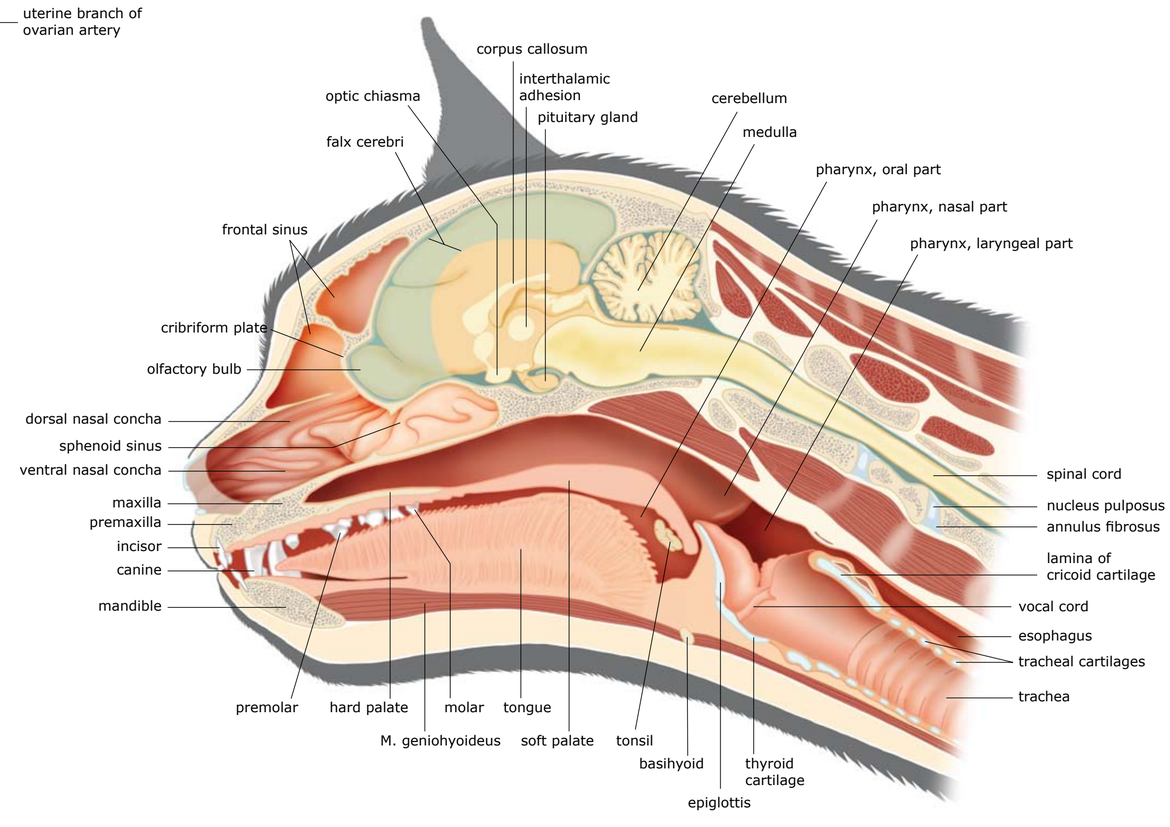

Virbac Medical
© Virbac

concept, design & anatomical illustrations: Maartje Kunen www.maartjekunen.nl text & scientific support: Wim Kersten, Faculty of Veterinary Medicine, Utrecht, the Netherlands

Virbac ANIMAL HEALTH